



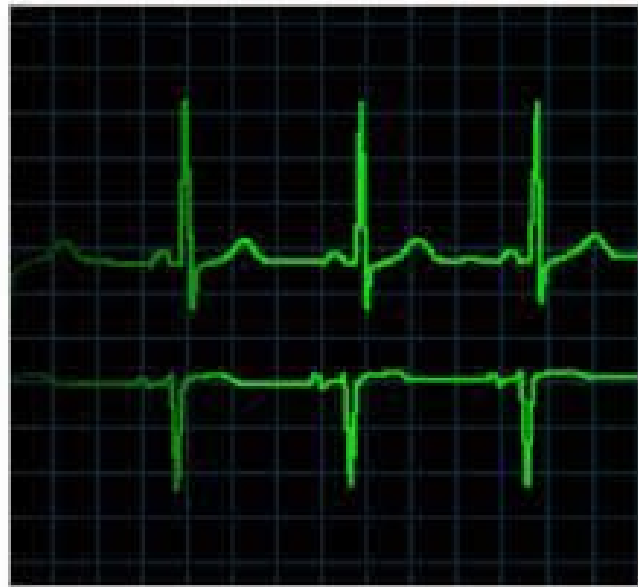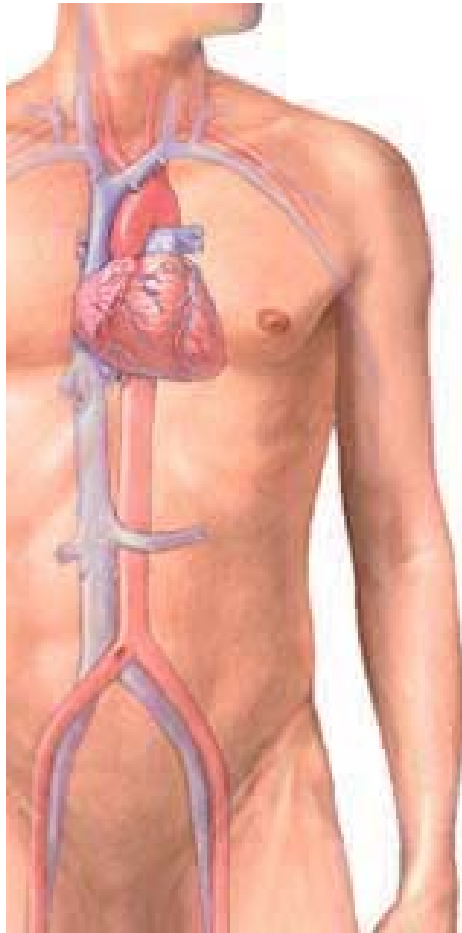
# Electrocardiograma (ECG)

---

**Exemplos**

# Traçado Normal

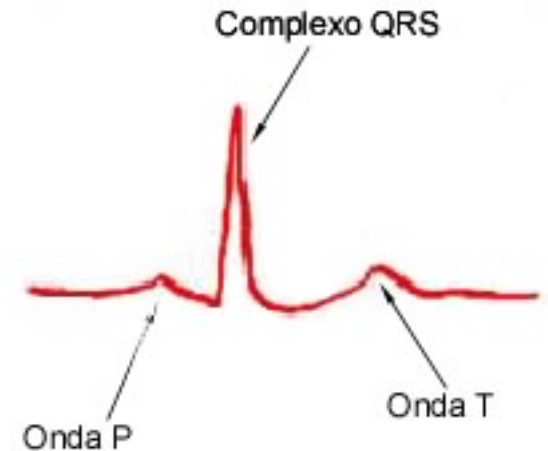
---



# Valores Normais:

---

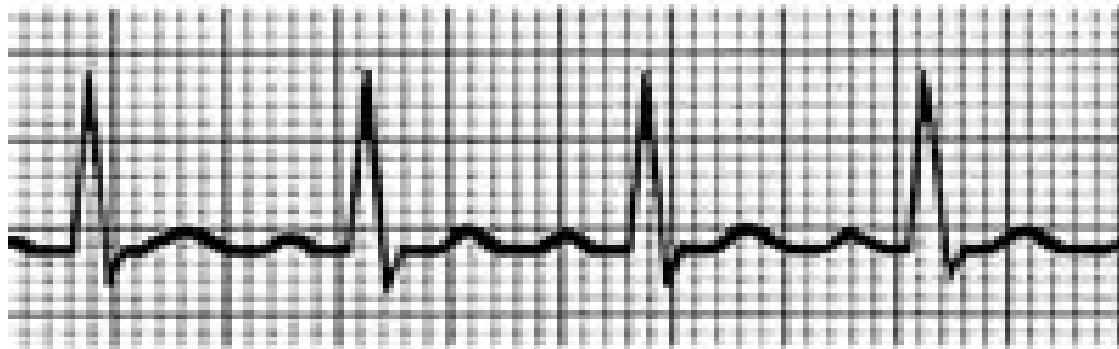- 60 a 100 batimentos por minuto
- Ritmo consistente e uniforme



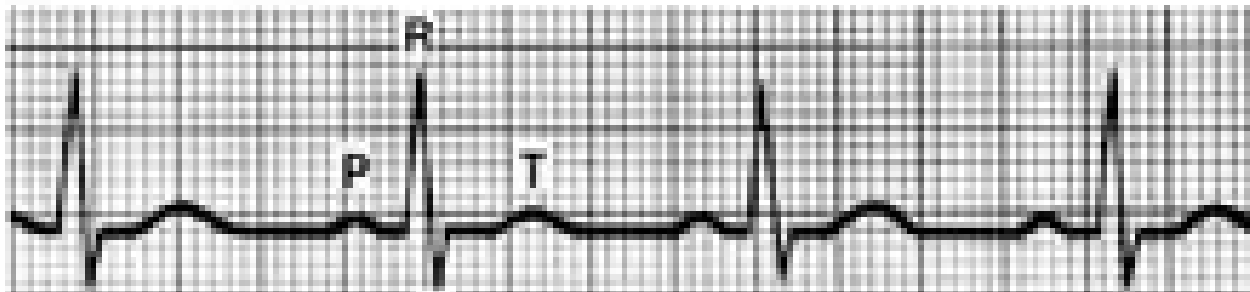
# Taquicardia

---

## Taquicardia sinusal



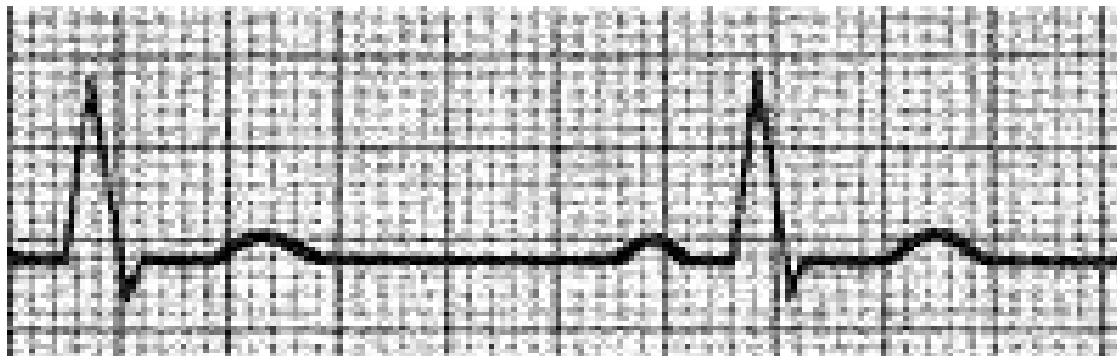
## Normal



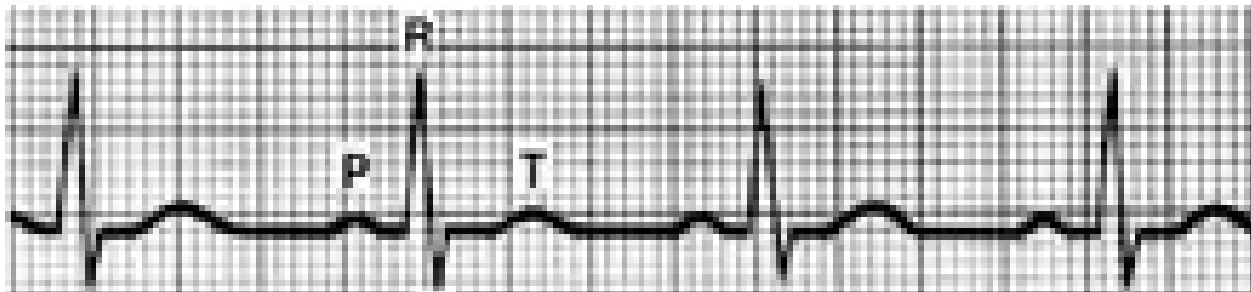
# Bradycardia

---

## Bradycardia sinusual

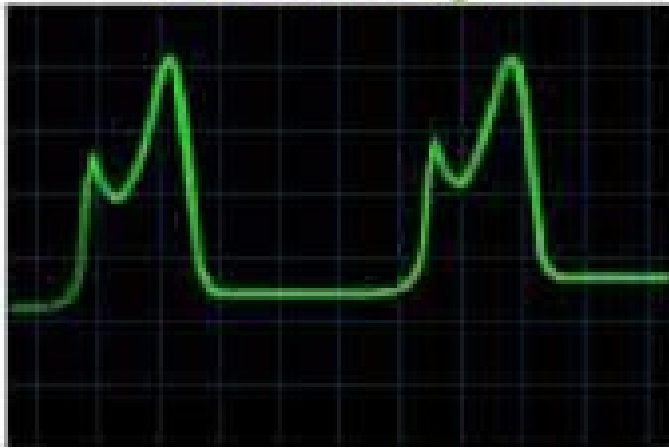

## Normal

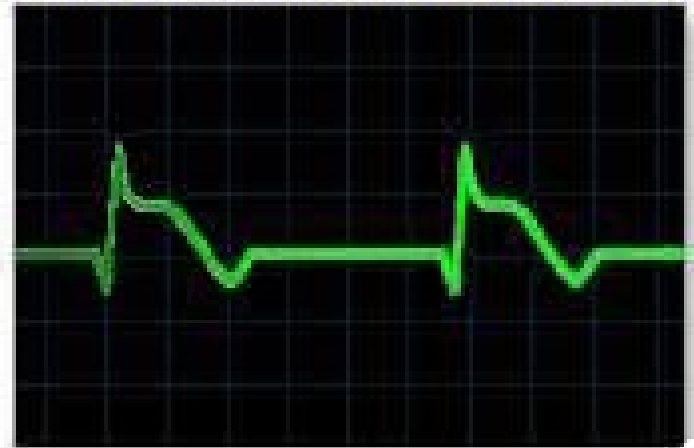

# Evolução do enfarte do miocárdio

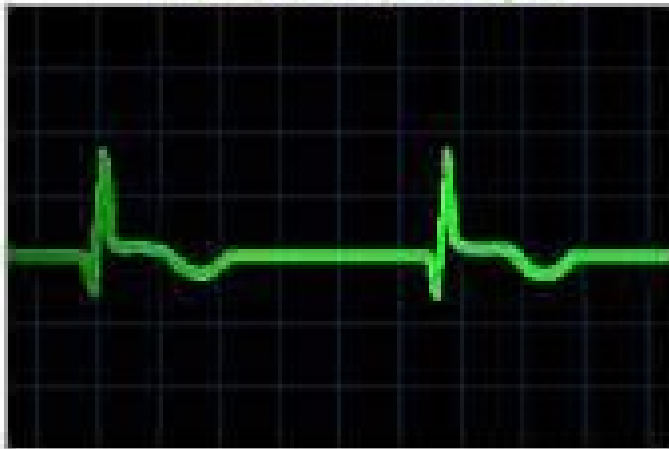Fase muito aguda



Fase inteiramente envolvida



Fase de resolução



Fase crónica estabilizada

